

## RECURRENT NASOPHARYNGEAL SQUAMOUS CELL CARCINOMA

---



Seoul, Korea CyberKnife® Team:

Radiation Oncologists: Seong-Yul Yoo, M.D.  
Chul-Koo Cho, M.D.  
KwangMo Yang, M.D.  
Mi Sook Kim, M.D.  
Hyung-Jun Yoo, M.D.

Medical Physicist: Dong-Han Lee, M.S.

CyberKnife Center: Korea Institute of Radiological and  
Medical Sciences  
Korea Cancer Center Hospital  
Seoul, Korea

## RECURRENT NASOPHARYNGEAL SQUAMOUS CELL CARCINOMA

### DEMOGRAPHICS

**Sex:** Male  
**Age:** 64 years  
**Histology:** Squamous Cell Carcinoma - IV (T4N0)

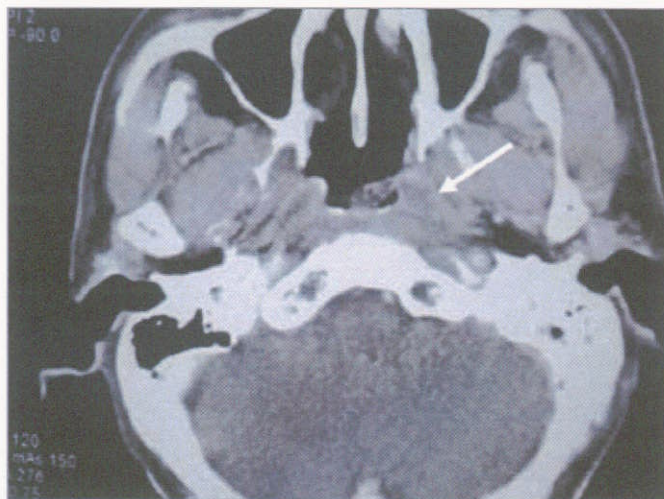
### CLINICAL HISTORY

**Referred by:** Head & Neck Surgery  
**Previous Treatment:** Conventional radiotherapy to the nasopharynx

### Case History

The patient was referred to Korea Institute of Radiological and Medical Sciences complaining of headache and dizziness that had been present for four months. He was diagnosed with stage IV (T4N0) nasopharyngeal carcinoma (NPC) with skull base involvement. The patient was treated with conventional radiotherapy as follows: 70 Gy over 7 weeks to the nasopharynx and 54 Gy over 6 weeks to the neck. Following treatment, there was no visible tumor mass on endoscopic examination.

The patient continued to suffer from headaches. Eight months after the initial presentation, CT and PET examination revealed a recurring mass in the left Rosenmuller fossa of the nasopharynx. The mass was confirmed by endoscopy. No signs of cranial nerve involvement were identified and the patient was referred for CyberKnife® treatment.



*Pre-CyberKnife CT scan shows recurrent lesion in the left wall of the nasopharynx.*

### CyberKnife Treatment Rationale

Radiotherapy is the standard treatment for patients with non-metastatic NPC. The local control rate of NPC depends on the T-stage of the disease. For stages T1 and T2, the local control rate ranges from about 75 to 90%; for stage T4, the local control rate ranges from about 40 to 65%.<sup>1,2,3</sup>

The standard treatment for recurrent NPC following external beam radiotherapy is re-irradiation. Salvage surgery to the nasopharynx is a very difficult procedure and is associated with high mortality and morbidity. If the tumor is located in or has invaded the skull base, surgical options are even further limited. Despite aggressive therapy, most patients with recurrent NPC experience poor tumor control and a significant risk of late complications from repeat radiotherapy.<sup>4,5</sup>

Radiosurgery is a practical alternative for both boost therapy after external beam radiotherapy and salvage therapy in patients with recurrent NPC. In one study all 23 patients receiving linac-based stereotactic radiosurgery as a boost following fractionated radiation therapy were locally controlled at a mean follow-up of 21 months.<sup>6</sup> Two-year local control rates of linac-based radiosurgery for salvage therapy after previous external beam radiotherapy were reported in two studies to be 72-74%.<sup>7,8</sup> In our experience at KCCH, the local control rate of NPC treated with CyberKnife radiosurgery is about 80% without serious complications.



## RECURRENT NASOPHARYNGEAL SQUAMOUS CELL CARCINOMA

### TREATMENT DETAILS

**Tumor Volume:** 1.6 cm<sup>3</sup>  
**Imaging Technique(s):** CT, PET  
**Rx Dose & Isodose:** 27 Gy to 78%  
**Conformality Index:** 1.64  
**Tumor Coverage:** 95%  
**Number of Beams:** 184

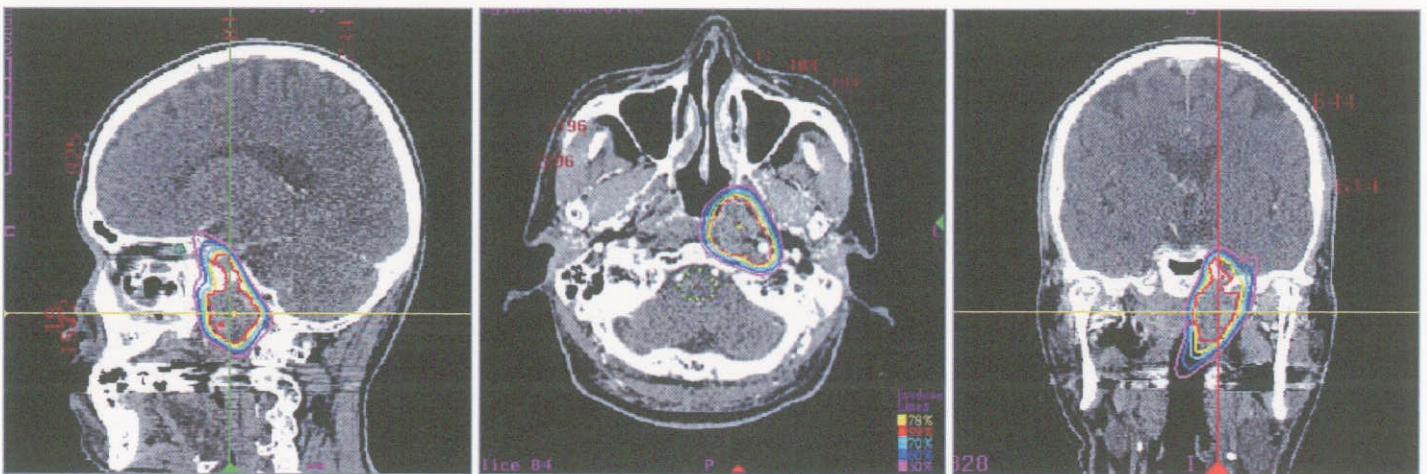
**Fractions / Treatment Time:** 3 @ 52 minutes  
**Path Template:** 3 path 800 mm  
**Tracking Method:** 6D Skull Tracking  
**Collimator(s):** 12.5 mm and 15 mm

### Treatment Planning Process

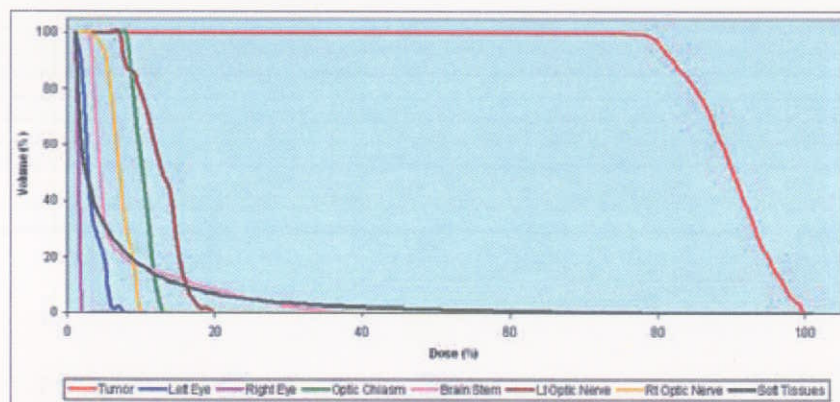
The tumor was located in the left lateral wall of the nasopharynx, extending from the skull base down to the upper wall of the pharynx. The target volume (GTV) included the vascular foramen of the skull base. A PTV was delineated by adding margins of 3 mm to the GTV. The optic chiasm and the brainstem were contoured in order to minimize dose to these critical structures. The 78% isodose line represents the prescribed dose of 27 Gy to the tumor. This isodose line covered 95% of the PTV with a conformality index of 1.64.

### Treatment Delivery

The patient was immobilized using the same thermoplastic mask worn during the CT. The treatment utilized 184 separately targeted beams with the 12.5 and 15 mm collimators and was completed in 52 minutes per fraction. The tumor volume measured 1.6 cc. Only 0.15 cc of the optic chiasm received a dose greater than 5 Gy. The volume of brainstem receiving 10 Gy was 0.3 cc. The patient reported no adverse side effects from the treatment delivery.



Sagittal, axial & coronal treatment planning images. The yellow line is the 78% isodose contour representing a prescribed dose of 27 Gy.



Dose statistics and dose volume histogram (DVH) for target volume and all critical structures.