

RECURRENT NASOPHARYNGEAL SQUAMOUS CELL CARCINOMA



Seoul, Korea CyberKnife® Team:

Radiation Oncologists: Seong-Yul Yoo, M.D.
Chul-Koo Cho, M.D.
KwangMo Yang, M.D.
Mi Sook Kim, M.D.
Hyung-Jun Yoo, M.D.

Medical Physicist: Dong-Han Lee, M.S.

CyberKnife Center: Korea Institute of Radiological and
Medical Sciences
Korea Cancer Center Hospital
Seoul, Korea

RECURRENT NASOPHARYNGEAL SQUAMOUS CELL CARCINOMA

DEMOGRAPHICS

Sex: Male
Age: 64 years
Histology: Squamous Cell Carcinoma - IV (T4N0)

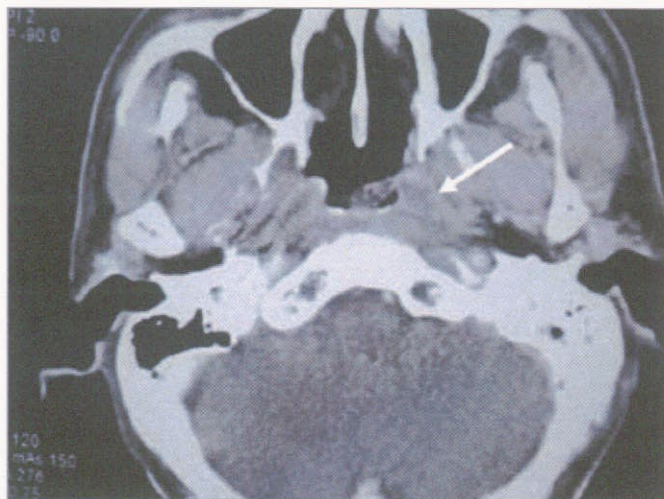
CLINICAL HISTORY

Referred by: Head & Neck Surgery
Previous Treatment: Conventional radiotherapy to the nasopharynx

Case History

The patient was referred to Korea Institute of Radiological and Medical Sciences complaining of headache and dizziness that had been present for four months. He was diagnosed with stage IV (T4N0) nasopharyngeal carcinoma (NPC) with skull base involvement. The patient was treated with conventional radiotherapy as follows: 70 Gy over 7 weeks to the nasopharynx and 54 Gy over 6 weeks to the neck. Following treatment, there was no visible tumor mass on endoscopic examination.

The patient continued to suffer from headaches. Eight months after the initial presentation, CT and PET examination revealed a recurring mass in the left Rosenmuller fossa of the nasopharynx. The mass was confirmed by endoscopy. No signs of cranial nerve involvement were identified and the patient was referred for CyberKnife® treatment.



Pre-CyberKnife CT scan shows recurrent lesion in the left wall of the nasopharynx.

CyberKnife Treatment Rationale

Radiotherapy is the standard treatment for patients with non-metastatic NPC. The local control rate of NPC depends on the T-stage of the disease. For stages T1 and T2, the local control rate ranges from about 75 to 90%; for stage T4, the local control rate ranges from about 40 to 65%.^{1,2,3}

The standard treatment for recurrent NPC following external beam radiotherapy is re-irradiation. Salvage surgery to the nasopharynx is a very difficult procedure and is associated with high mortality and morbidity. If the tumor is located in or has invaded the skull base, surgical options are even further limited. Despite aggressive therapy, most patients with recurrent NPC experience poor tumor control and a significant risk of late complications from repeat radiotherapy.^{4,5}

Radiosurgery is a practical alternative for both boost therapy after external beam radiotherapy and salvage therapy in patients with recurrent NPC. In one study all 23 patients receiving linac-based stereotactic radiosurgery as a boost following fractionated radiation therapy were locally controlled at a mean follow-up of 21 months.⁶ Two-year local control rates of linac-based radiosurgery for salvage therapy after previous external beam radiotherapy were reported in two studies to be 72-74%.^{7,8} In our experience at KCCH, the local control rate of NPC treated with CyberKnife radiosurgery is about 80% without serious complications.

RECURRENT NASOPHARYNGEAL SQUAMOUS CELL CARCINOMA

TREATMENT DETAILS

Tumor Volume: 1.6 cm³
Imaging Technique(s): CT, PET
Rx Dose & Isodose: 27 Gy to 78%
Conformality Index: 1.64
Tumor Coverage: 95%
Number of Beams: 184

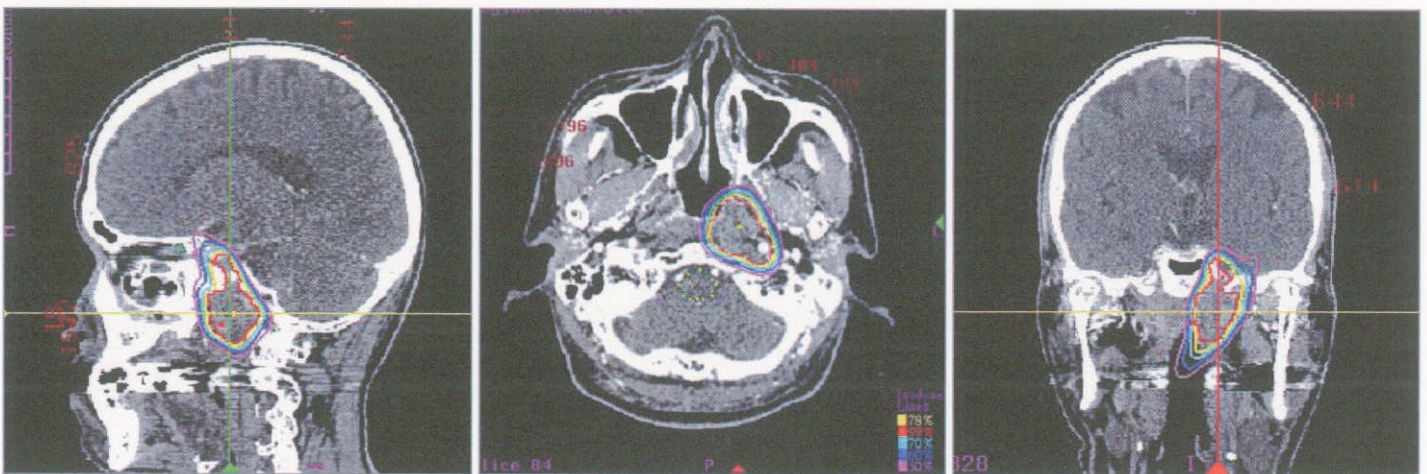
Fractions / Treatment Time: 3 @ 52 minutes
Path Template: 3 path 800 mm
Tracking Method: 6D Skull Tracking
Collimator(s): 12.5 mm and 15 mm

Treatment Planning Process

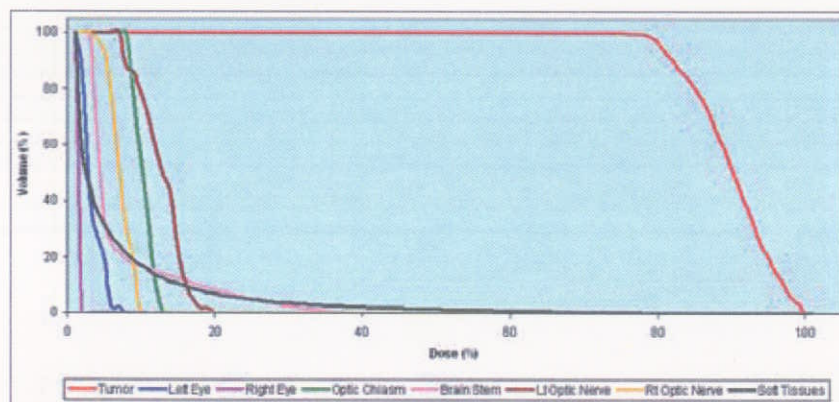
The tumor was located in the left lateral wall of the nasopharynx, extending from the skull base down to the upper wall of the pharynx. The target volume (GTV) included the vascular foramen of the skull base. A PTV was delineated by adding margins of 3 mm to the GTV. The optic chiasm and the brainstem were contoured in order to minimize dose to these critical structures. The 78% isodose line represents the prescribed dose of 27 Gy to the tumor. This isodose line covered 95% of the PTV with a conformality index of 1.64.

Treatment Delivery

The patient was immobilized using the same thermoplastic mask worn during the CT. The treatment utilized 184 separately targeted beams with the 12.5 and 15 mm collimators and was completed in 52 minutes per fraction. The tumor volume measured 1.6 cc. Only 0.15 cc of the optic chiasm received a dose greater than 5 Gy. The volume of brainstem receiving 10 Gy was 0.3 cc. The patient reported no adverse side effects from the treatment delivery.



Sagittal, axial & coronal treatment planning images. The yellow line is the 78% isodose contour representing a prescribed dose of 27 Gy.



Dose statistics and dose volume histogram (DVH) for target volume and all critical structures.

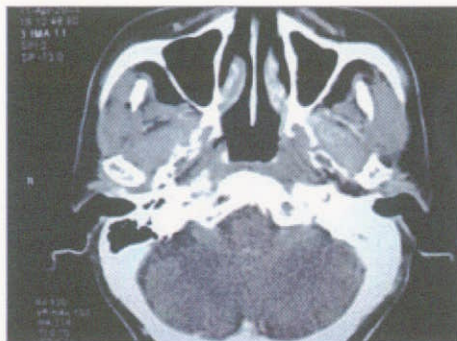
RECURRENT NASOPHARYNGEAL SQUAMOUS CELL CARCINOMA

Outcome and Follow-Up

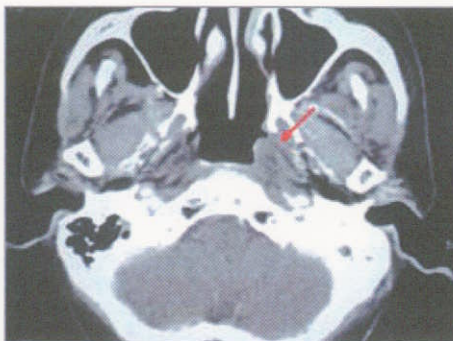
This patient reported no adverse side effects from the treatment delivery based on monthly follow-up exams. A CT scan acquired 3 months after treatment revealed decreased extent of the nasopharyngeal mass. Additional CT scans at 6 and 18 months and a PET scan at 21 months showed no evidence of disease.

Conclusion and CyberKnife® Advantages

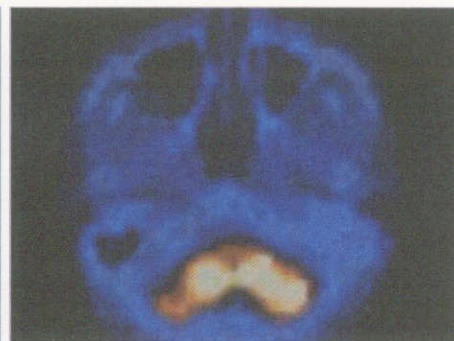
- The CyberKnife Radiosurgery® System delivered a painless, complication-free treatment to this patient with a recurrent NPC tumor who had received previous conventional external beam radiotherapy
- This Robotic Radiosurgery treatment achieved local control with no radiographic evidence of disease nearly two years after treatment
- Despite aggressive therapy, most patients with recurrent NPC experience poor tumor control and a significant risk of late complications from repeat radiotherapy.^{4,5} CyberKnife radiosurgery achieves excellent local control rates in NPC patients as boost therapy after external beam radiotherapy.⁹ It also represents a practical alternative for salvage therapy in patients with recurrent NPC



Post-CyberKnife CT taken at 6 months shows no identifiable tumor mass.



18 month follow-up CT reveals absence of tumor.



PET scan at 21 months is normal, showing no evidence of disease.

KOREA INSTITUTE OF RADIOLOGICAL & MEDICAL SCIENCES (KIRAMS) (www.kirams.re.kr)

Korea Institute of Radiological and Medical Sciences (KIRAMS) is the most prestigious cancer institute in Korea. This 42-year old cancer center is recognized world wide for cancer research in a variety of clinical applications. Installed in June 2002, its CyberKnife was the first in Korea. The CyberKnife Center at Korea Cancer Center Hospital (KCCH) is supported by a team of Radiation Oncologists, Neurosurgeons, Medical Physicists and other medical specialists. In June 2005, the center reached the 1,000th patient milestone coinciding with its three-year anniversary. Non-CNS Body Radiosurgery represents more than 60% of patients treated. Pancreas and paraaortic metastasis from cervical and rectal cancer have responded in remarkable fashion to CyberKnife treatment. KCCH was recently named as the International Education Center for the practice of CyberKnife users in Asia.

References

1. Vikram B, Mishra UB, Strong EW, et al: Patterns of failure in carcinoma of the nasopharynx. I. Failure at the primary site. *Int J Radiat Oncol Biol Phys* 11: 1455-1459, 1985.
2. Perez CA, Devineni VR, Marcial-Vega V, et al: Carcinoma of the nasopharynx: factors affecting prognosis. *Int J Radiat Oncol Biol Phys* 23: 271-280, 1992.
3. Sanguineti G, Geara FB, Garden AS, et al: Carcinoma of the nasopharynx treated by radiotherapy alone: determinants of local and regional control. *Int J Radiat Oncol Biol Phys* 37: 985-996, 1997.
4. Hwang J-M, Fu KK, Phillips TL: Results and prognostic factors in the retreatment of locally recurrent nasopharyngeal carcinoma. *Int J Radiat Oncol Biol Phys* 41: 1099-1111, 1998.
5. Lee AWM, Foo W, Law SCK, et al: Total biological effect on late reactive tissues following reirradiation for recurrent nasopharyngeal carcinoma. *Int J Radiat Oncol Biol Phys* 46: 865-872, 2000.
6. Tate DJ, Adler Jr JR, Chang SD, et al: Stereotactic radiosurgical boost following radiotherapy in primary nasopharyngeal carcinoma: impact on local control. *Int J Radiat Oncol Biol Phys* 45: 915-921, 1999.
7. Xiao JP, Xu GZ, Miao YJ: Fractionated stereotactic radiosurgery for locally recurrent or residual nasopharyngeal carcinoma. *Int J Radiat Oncol Biol Phys* 51: 164-170, 2001.
8. Pai PC, Chuang CC, Wei KC, et al: Stereotactic radiosurgery for locally recurrent nasopharyngeal carcinoma. *Head Neck* 24: 748-753, 2002.
9. Le Q-T, Tate D, Koong A, et al: Improved local control with stereotactic radiosurgical boost in patients with nasopharyngeal carcinoma. *Int J Radiat Oncol Biol Phys* 56: 1046-1054, 2003.

