

**CYBERKNIFE® MONOTHERAPY FOR
LOW-RISK PROSTATE CANCER:
HIGH DOSE-RATE BRACHYTHERAPY
FRACTIONATION AND DOSE GRADIENTS**



CyberKnife® Centers of San Diego CyberKnife Team:

Radiation Oncologist: Donald B. Fuller, M.D.

Medical Physicist: Haoran Jin, Ph.D.

CyberKnife Center: CyberKnife Centers of San Diego
San Diego, CA

DEMOGRAPHICS

Sex: Male
Age: 76 years
Histology: Prostate Adenocarcinoma

CLINICAL HISTORY

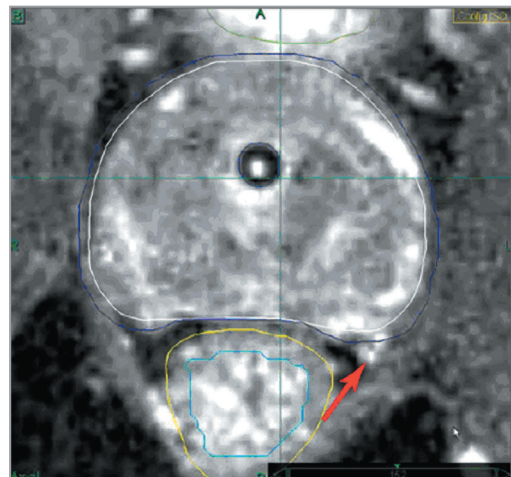
Past Medical History: None

Case History

This 76-year-old man presented during a routine check-up with a PSA of 7.7 ng/ml. A biopsy four months later revealed adenocarcinoma involving 30% of the submitted tissue with a Gleason score of 3+3=6. A subsequent bone scan and CT of the abdomen and pelvis showed no evidence of metastatic disease. PSA analysis was repeated two months later, and measured 9.4 ng/ml. In his initial evaluation, he had an International Prostate Symptom Score (IPSS) of 4 and Sexual Health Inventory for Men (SHIM) score of 23; the lesion was staged as T2a at the right base. The patient was diagnosed as having low-risk, organ confined prostate cancer.

CyberKnife® Treatment Rationale

Several treatment options were discussed with the patient, including radical prostatectomy, external beam radiotherapy, and brachytherapy. The unique radiobiology of prostate cancer suggests that the disease is particularly sensitive to large-dose-per-fraction (hypofractionated) radiation treatment regimens.¹ In support of this, good biochemical disease control with few serious side effects has recently been reported for the hypofractionated approach referred to as high dose rate (HDR) brachytherapy.⁴ The CyberKnife® Centers of San Diego developed a CyberKnife-based hypofractionated prostate treatment that effectively reproduces the dose, dose distribution, and fractionation of HDR brachytherapy.³ This approach has been designed to escalate the dose to the peripheral zone of the prostate, which typically harbors the majority of cancer cells.⁴ This treatment option allows patients to benefit from HDR brachytherapy dose sculpting while avoiding the invasive aspect of indwelling catheter placement required of the HDR brachytherapy procedure.



T1-weighted, gadolinium-enhanced MRI treatment planning image; GTV (prostate) defined by white line; planning target volume (PTV) defined by blue line; rectal mucosa defined by yellow and turquoise lines. Note that the 1.5T MRI renders the neurovascular bundle (NVB) visible (red arrow) so that a treatment plan can be constructed that limits dose to this structure.

TREATMENT DETAILS

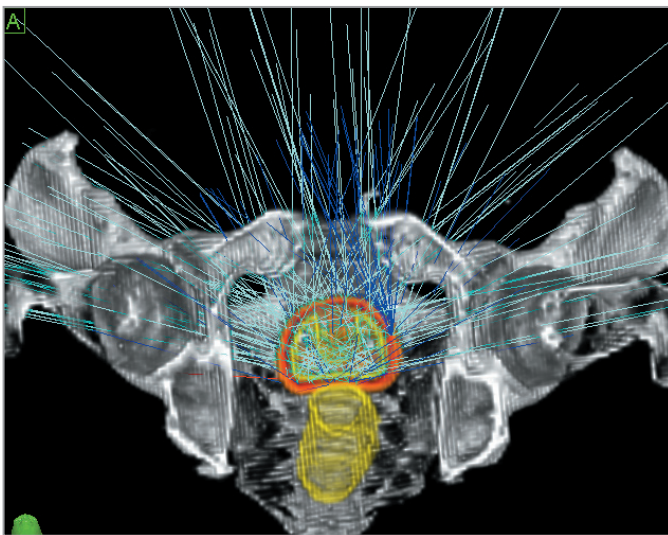
Prostate Volume: 55 cm³
Imaging Technique(s): CT, 1.5T MRI
Rx Dose & Isodose: 38 Gy to 57% isodose line
Number of Beams: 261

Fractions: 4
Path Template: Single collimator long path
Tracking Method: 6D fiducial tracking
Collimator(s): 15 mm

Planning Process

CT and MRI imaging were used for the planning process. The MRI images were fused to the CT image set to better define the prostate capsule, rectal mucosa, neurovascular bundle (NVB) and the penile bulb. For both image sets, a Foley catheter was used to fill the bladder with 100 ml of H₂O, to aid in identifying the urethra and bladder. The rectum was emptied by administration of a Fleet Enema®. The planning treatment volume was created by expanding the prostate volume in all directions by 2 mm, except posteriorly where the prostate abutted the rectum. In this region the margin expansion was reduced to zero. Constraints provided by the radiation oncologist resulted in the following doses to critical structures:

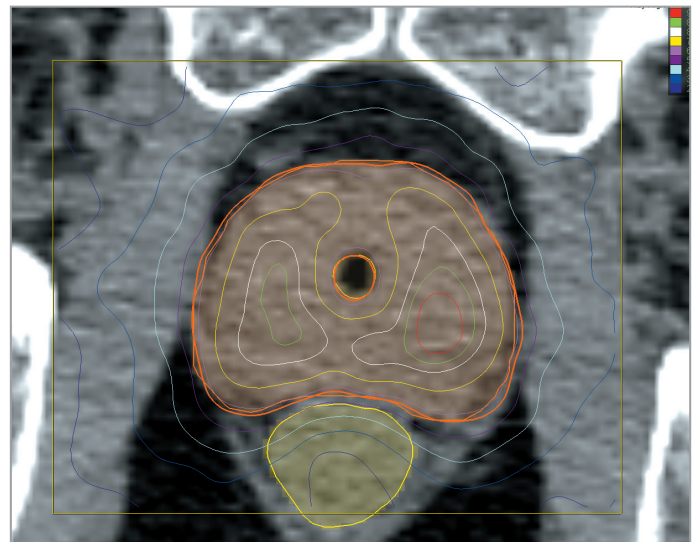
Structure	Dose parameters
Urethra	D _{max} – 44 Gy (116%); Median – 38.4 Gy (101%)
Rectum Outer Wall	D _{max} – 34.7 Gy (91%)
Rectum Mucosa	D _{max} – 25.3 Gy (67%)
Penile Bulb	D _{max} – 22.7 Gy (60%); D50 – 7.3 Gy (19%)
Neurovascular Bundles	Steep gradient: 48 Gy (126%) - 26.8 Gy (71%)



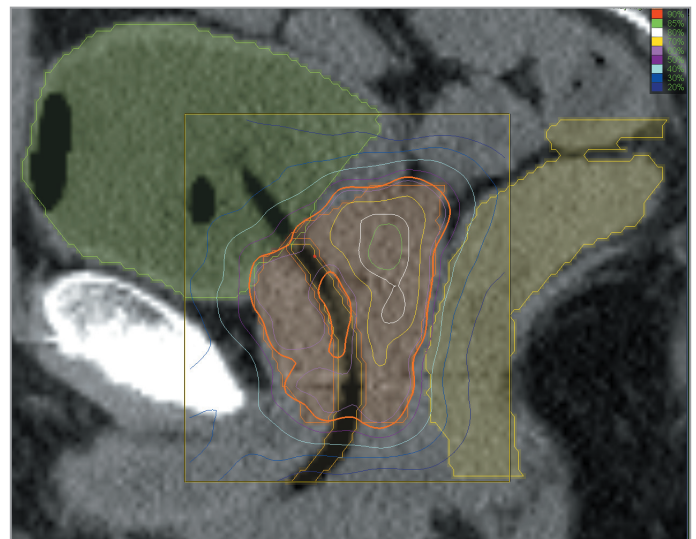
Three-dimensional rendering of beam trajectories to the PTV.

Treatment Delivery

Four fiducials were implanted transperineally into the prostate prior to the planning CT scan. A treatment plan was constructed based on co-registered CT/MRI scans. The patient was treated with a total dose of 38 Gy delivered in 4 equal fractions occurring on consecutive days.



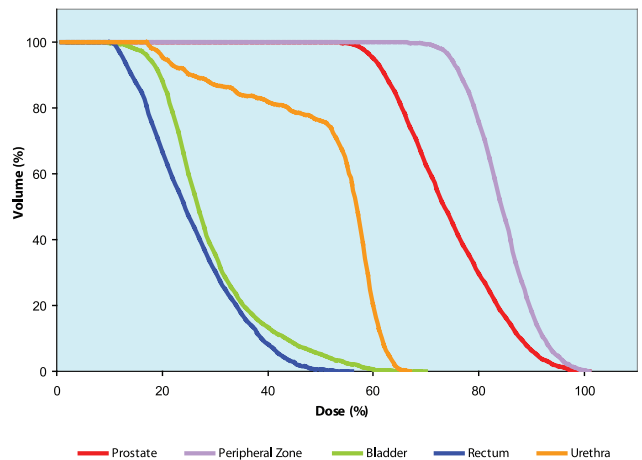
Axial planning image demonstrating extreme conformality, which results in the potential to spare the NVB from the full dose zone in selected low-risk patients. The prescription isodose line is shown in orange (57%). Note that the regions of high dose within the prostate correspond approximately to the peripheral zone.



Sagittal planning image demonstrating a very sharp dose gradient sparing the rectum and urethra. Prescription dose line is orange (57%).

Outcome and Follow-Up

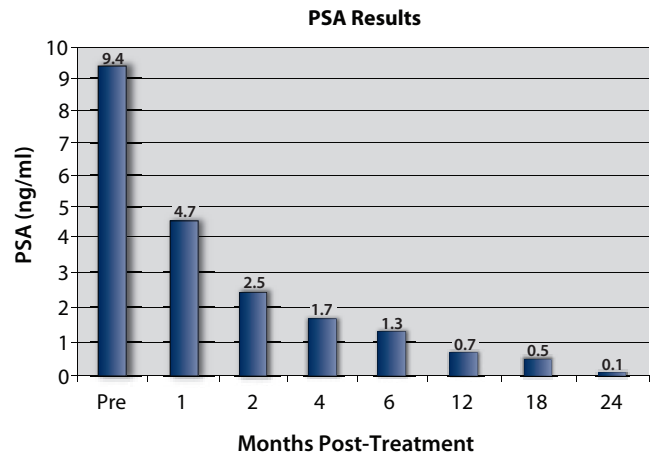
- Two weeks post-treatment, the patient experienced increased frequency of bowel movements (BM) and acute dysuria, and was prescribed Flomax®
- One month after the treatment, the patient’s dysuria and increased BM frequency improved; PSA dropped to 4.7 ng/ml from a pretreatment level of 9.4 ng/ml
- At the 2-month follow-up, the patient’s dysuria and increased BM frequency had resolved; patient’s IPSS and SHIM score were at baseline levels; PSA continued to decline, measured at 2.5 ng/ml
- During the 18-month follow-up period, the patient’s PSA level continued to decline steadily, reaching 0.5 ng/ml (see figure); the patient’s IPSS was 5 and his SHIM score was 16



Dose-volume histogram showing escalation of dose to the peripheral zone of the prostate (lavender line) and sparing of nearby organs at risk.

Conclusion

- The CyberKnife® System successfully reproduced an HDR-like dose distribution, delivering treatment in a minimally invasive fashion
- Treatment-related toxicity was mild (grade I - II urinary symptoms) and resolved over time in this first 18 months of follow up; further follow-up is required to assess chronic toxicity in this patient
- A significant reduction in PSA levels followed treatment throughout the first 18 months of follow-up



CYBERKNIFE CENTERS OF SAN DIEGO (www.sdcyberknife.com)

CyberKnife Centers of San Diego opened their first office in a patient friendly, centrally located San Diego location in June of 2006. To serve increasing demand from patients and referring physicians alike, the second CyberKnife Centers of San Diego office was opened in North Coastal San Diego County in November 2007. Prostate and lung cancer have been the two most prevalent CyberKnife applications to date in this practice, with the physicians and staff believing CyberKnife radiosurgery to represent paradigm-shifting technology for these and other cancer indications.

To contact a CyberKnife Center of San Diego, call 858-505-4100 or 800-470-1256.

References

1. King CR, Lehmann J, Adler JR, Hai J. CyberKnife radiotherapy for localized prostate cancer: rationale and technical feasibility. *Technol Cancer Res Treat.* 2003;2:25-30.
2. Grills IS, Martinez AA, Hollander M, Huang R, Goldman K, Chen PY, Gustafson GS. High dose rate brachytherapy as prostate cancer monotherapy reduces toxicity compared to low dose rate palladium seeds. *J Urol.* 2004;171:1098-1104.
3. Fuller DB, Naitoh J, Lee C, Hardy S, Jin H: Virtual HDR(SM) CyberKnife Treatment for Localized Prostatic Carcinoma: Dosimetry Comparison With HDR Brachytherapy and Preliminary Clinical Observations. *Int J Radiat Oncol Biol Phys* 70:1588-1597, 2008.
4. McNeal JE, Redwine EA, Freiha FS, Stamey TA. Zonal distribution of prostatic adenocarcinoma. Correlation with histologic pattern and direction of spread. *Am J Surg Pathol.* 1988;12:897-906.

